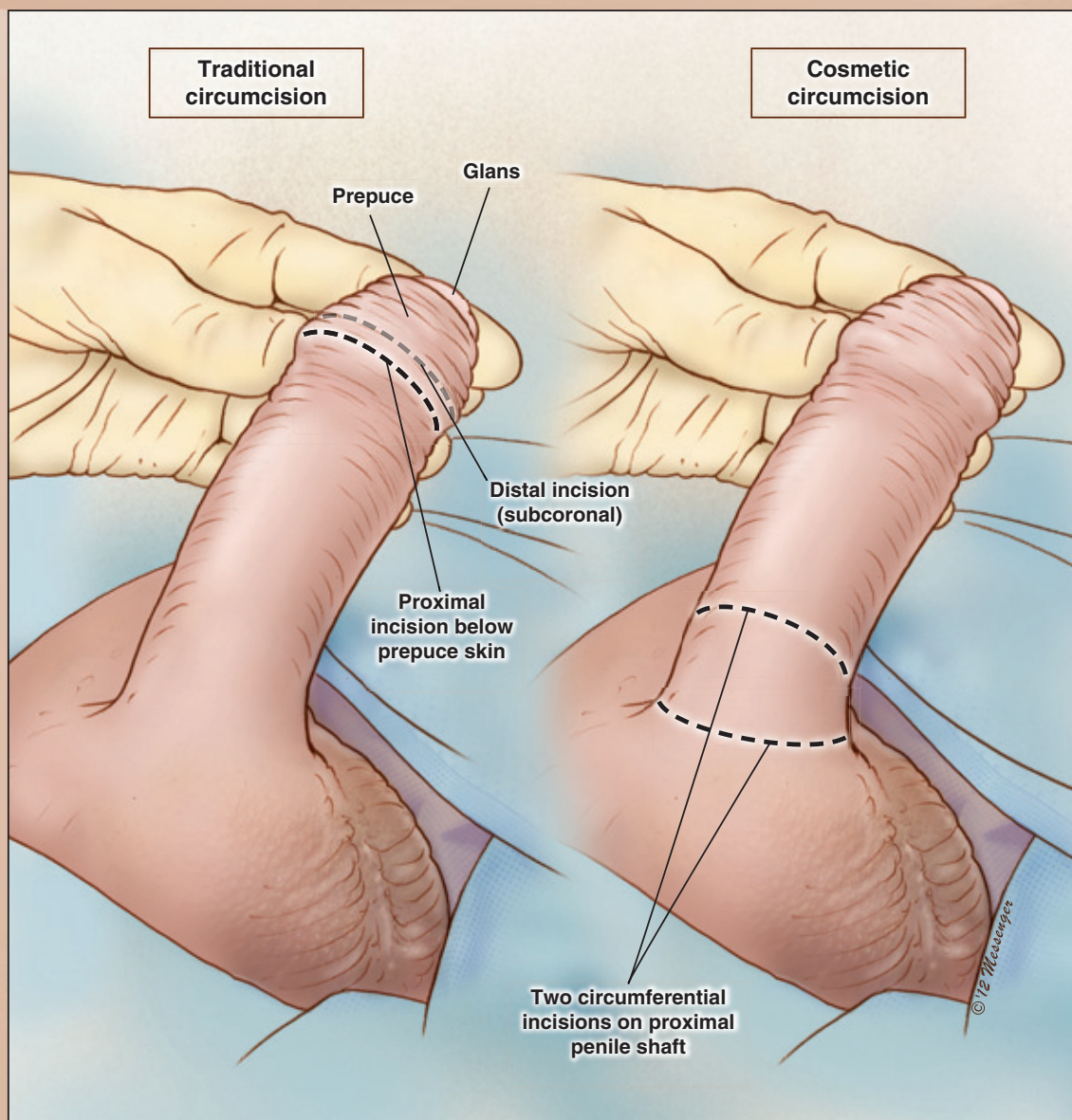


# Surgical Techniques

## The Cosmetic Circumcision

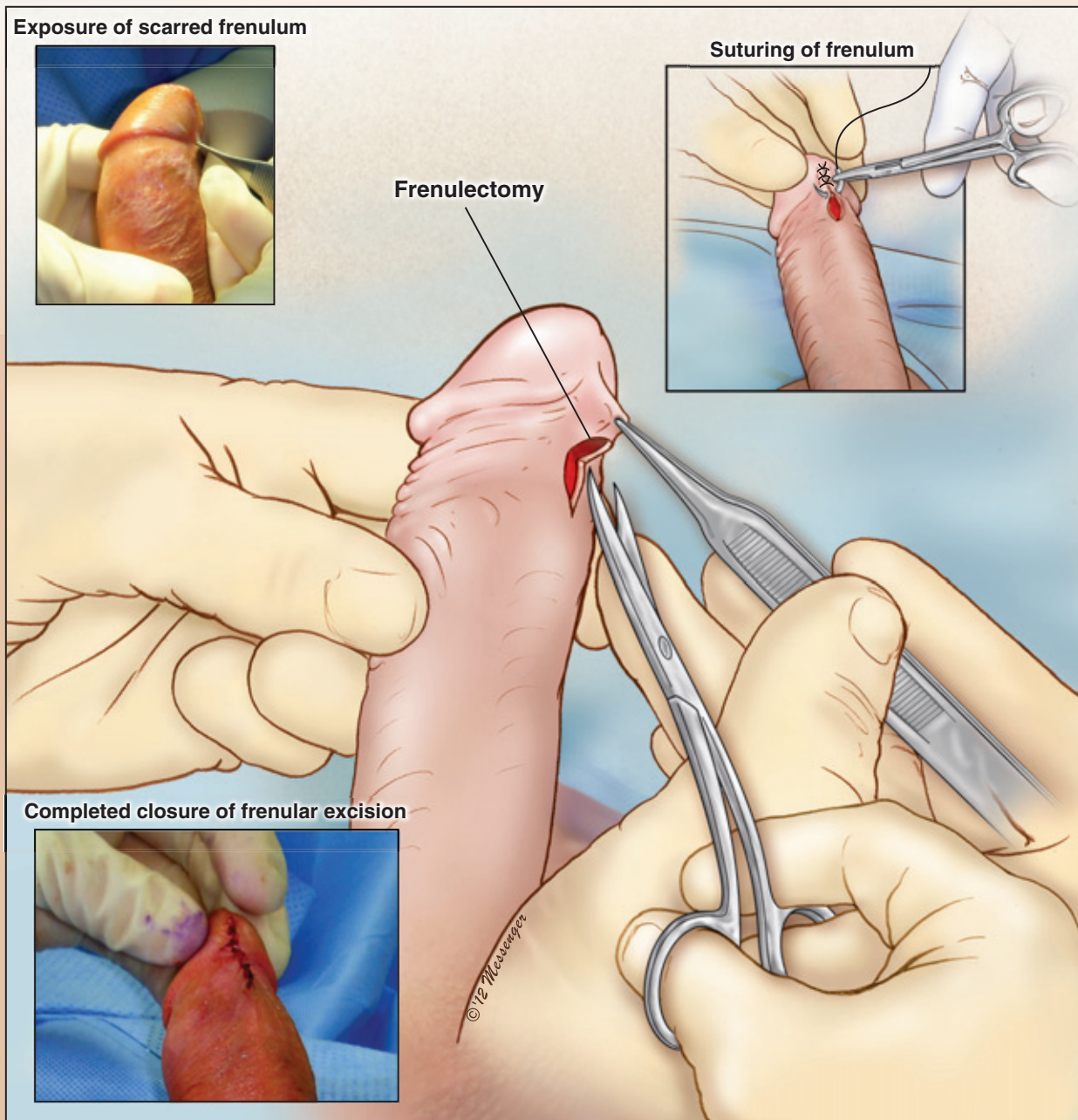
J. Francois Eid, MD

Advanced Urological Care, PC, New York, NY, USA



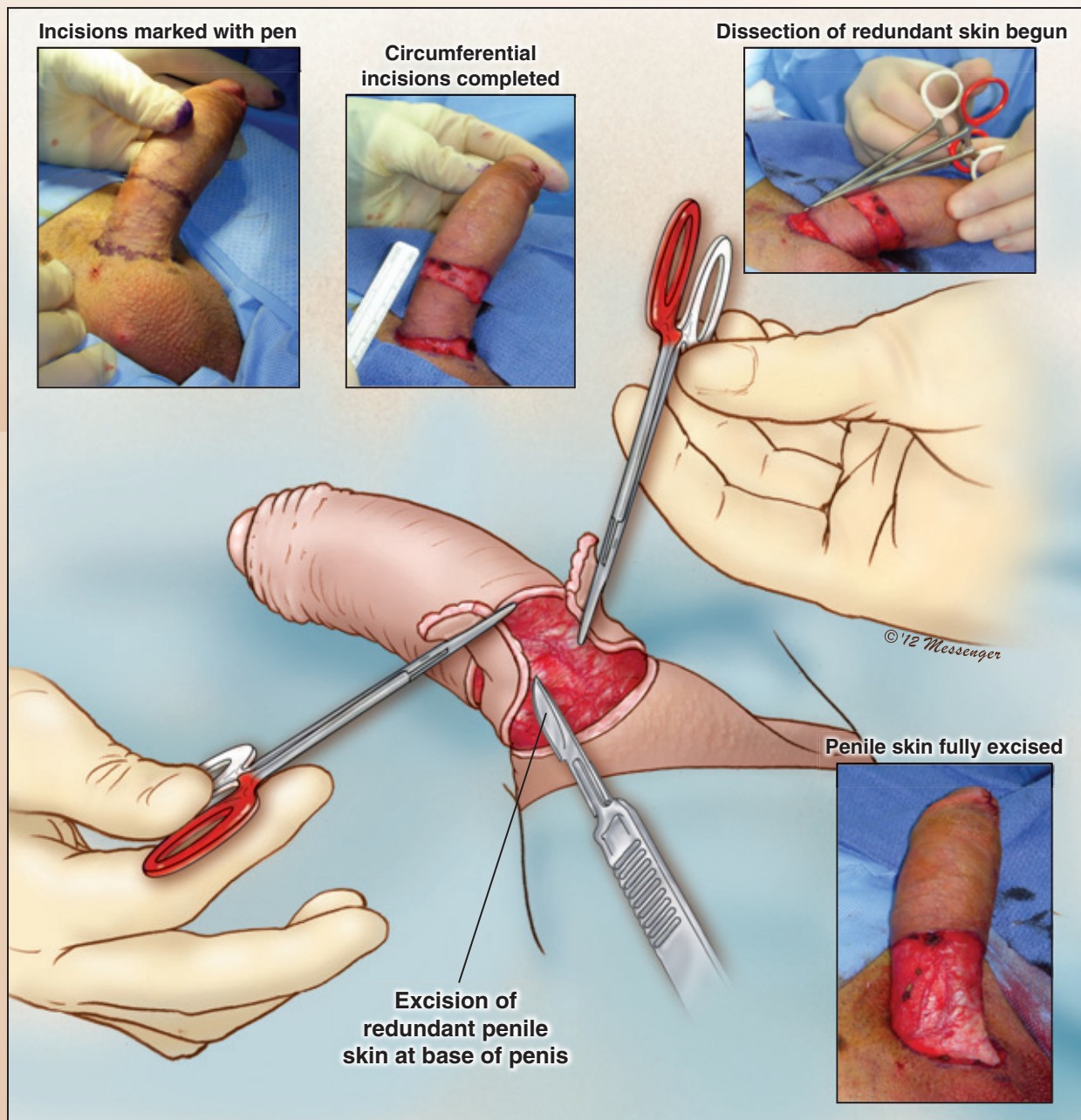
**FIGURE 1**

A penile injection of 10–20 mcg prostaglandin E1 is given with a 31-gauge 8-mm needle at the beginning of the case to provide the patient with an erection. This helps the surgeon determine how much skin needs to be removed. While the penis remains erect, the foreskin is pulled over the glans penis, and released. The skin at the base of the penile shaft is marked with a marking pen in a circumferential manner at the junction of the penis with the pubis on the dorsum and at the junction of the scrotal skin on the sides and the ventral aspect of the penile shaft.



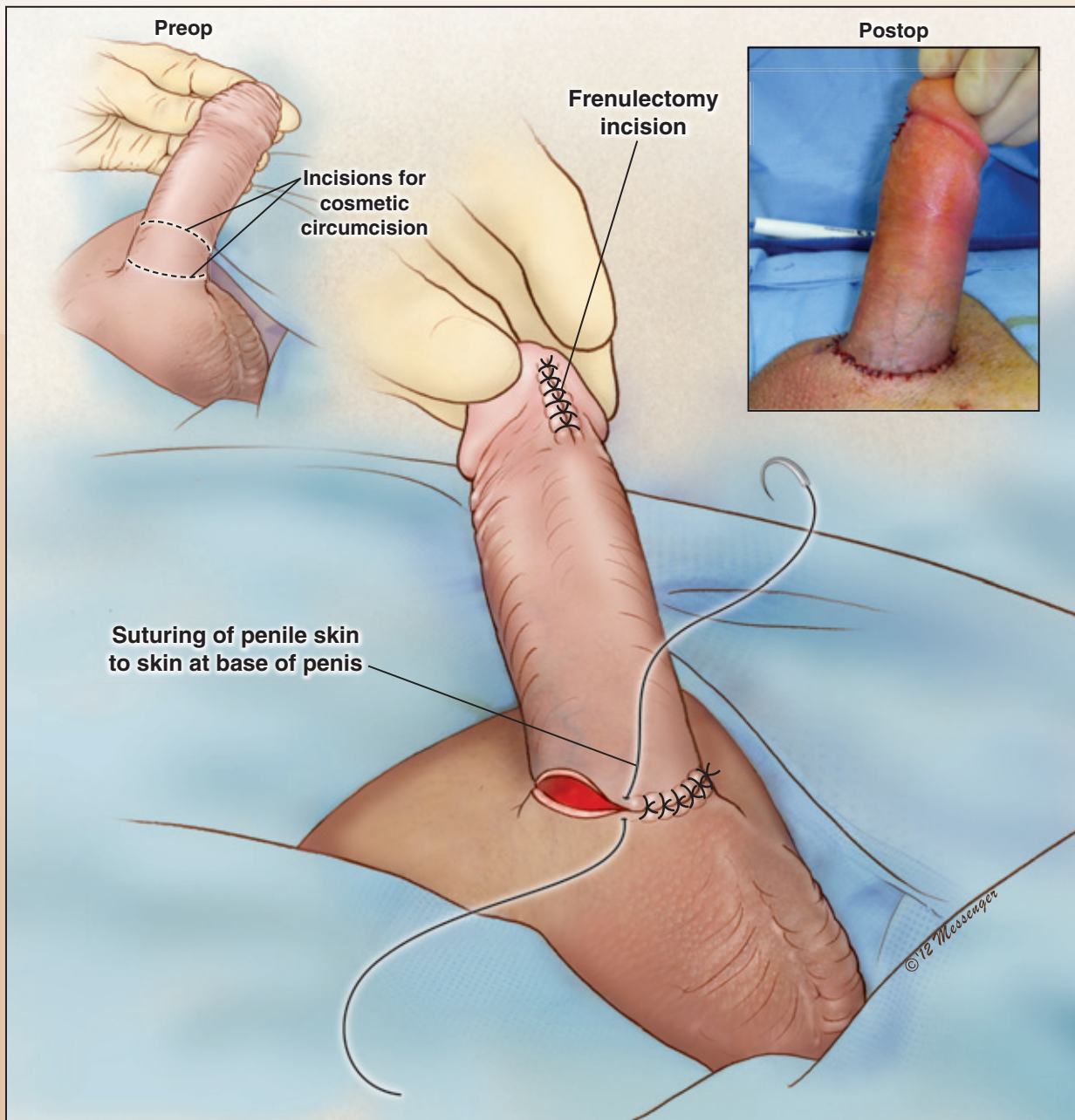
**FIGURE 2**

This technique avoids making an incision near the glans penis (traditional circumcision), preserves sensitivity, and completely hides the suture line. Also, post-operative pain and edema are minimized because the distal shaft of the penis is not degloved. The foreskin is retracted, and if needed, the frenulum is incised transversally and the skin reapproximated side-to-side. This releases the foreskin from the glans penis on the ventral side (frenuloplasty).



**FIGURE 3**

The foreskin is then retracted so that it is perfectly taut on the penile shaft, and a second mark is made with the marking pen in a circumferential manner starting on the dorsum and also ventrally maintaining traction on the skin of the penile shaft. After the skin incisions are made, the cuff of foreskin at the base of the penis is excised very superficially to avoid lymphatic vessel injury.



**FIGURE 4**

Reapproximation of the skin is performed in two planes in order to prevent excessive tension on suture line. Subcutaneous tissue is reapproximated with 3-0 Vicryl sutures (Ethicon, Inc., New Brunswick, NJ, USA) using an RB-1 needle in an interrupted fashion for each quadrant. The edges of the skin incisions are reapproximated at the base of the penile shaft with a combination of 3-0 and 4-0 chromic sutures.

The Surgical Techniques  
Section is sponsored in part by  
Coloplast

